

Management of Major Trauma: A Malaysian Perspective

Dr Kashfil Tengku, Dr Narisa Damanhuri, Dr Jazree Jamaluddin

July 2012

Volume 2

Issue 1

Doctors Academy Publications

The World Journal of Medical Education and Research (WJMER) is the online publication of the Doctors Academy Group of Educational Establishments. Published on a quarterly basis, its aim is to promote academia and research amongst all members of the multi-disciplinary healthcare team including doctors, dentists, scientists, and students of these specialties from all parts of the world. The principal objective of this journal is to encourage the aforementioned from developing countries in particular to publish their work. The journal intends to promote the healthy transfer of knowledge, opinions and expertise between those who have the benefit of cutting edge technology and those who need to innovate within their resource constraints. It is our hope that this will help to develop medical knowledge and to provide optimal clinical care in different settings all over the world. We envisage an incessant stream of information will flow along the channels that WJMER will create and that a surfeit of ideas will be gleaned from this process. We look forward to sharing these experiences with our readers in our subsequent editions. We are honoured to welcome you to WJMER.



DOCTORS
ACADEMY
Disseminating Medical Knowledge and Skills Globally



WJMER

World Journal of Medical Education and Research

An Official Publication of the Education and Research Division of Doctors Academy



The Role of Cell-Based Imaging in Drug Discovery

Antigen Microarrays for Rapid Screening of Rheumatoid Arthritis and Other Autoimmune Diseases

Abstracts from the International Academic & Research Conference 2012

Osteoradionecrosis (ORN) of the jaw

In this edition, these topics and more....

Management of Major Trauma:
A Malaysian Perspective

Assessment and Management of Head and
Spinal Cord Injuries

Role of Cloud Computing in Global Healthcare
Provision

Management of Major Trauma: A Malaysian Perspective

Dr. Kashfil Tengku, MBBS

Orthopaedic Resident

Sultan Abdul Halim Hospital, Sg Petani, Kedah, Malaysia

Dr. Narisa Damanhuri, MBChB

Family Medicine Resident

Sungai Petani Health Clinic, Kedah, Malaysia

*Address for Correspondence:*Dr Narisa Damanhuri: narisa.damanhuri@rocketmail.com**Dr. Jazree Jamaluddin, MB BCh BAO**

Chief Medical Officer, Department of Cardiothoracic

Surgery, Serdang Hospital, Selangor, Malaysia

Keywords:*ATLS, pelvic fractures, acute abdominal trauma, limb threatening injuries, amputations***Introduction**

Trauma and accidental injuries remain a leading cause of morbidity and mortality worldwide. With every death, two people suffer permanent disability. In the developing world, the impact is further pronounced in view of the increasing population and the associated use of motor vehicles. The society's livelihood depends on a full functioning body as manual labour contributes greatly to the workforce in developing countries hence families faced with disability would suffer tremendously as they are often dependent on a single bread-winner. Thus, establishment of functioning trauma care systems is crucial.

In developed countries, the increased awareness of seatbelts over the recent years has resulted in a reduced number of long bone traumas¹. In Malaysia road traffic accidents account for almost 80% of major trauma cases and it is the leading cause for admission to government hospitals. These trauma cases largely involve the younger population (between 15-24 years of age), 66% of which are associated with motorcyclists. This is becoming more pronounced as over speeding of motor bikes and lane splitting, more common amongst the younger age group, is on the rise. Poor awareness on importance of helmet use and motorcycle safety is also a contributing factor.

Trauma patients suffering from multiple injuries impose tremendous demands at all levels within hospitals particularly on those doctors, nurses and clinical officers caring for the patient within the first few hours of hospital admission. The first hour of admission, known as the "golden hour" for multiple trauma patients are critical in reducing permanent irreversible damage. Therefore in view of this, guidelines for major trauma care have been developed.

This article which will be accompanied by case studies summarizes important topics related to major trauma focusing on its management. The topics include:

- Management of patient according to the ATLS principles
- Management of pelvic fractures
- Management of acute abdominal trauma
- Management of limb threatening injuries
- Management of amputations to limbs or digits.

A. Advanced Trauma Life Support (ATLS) for major traumaPrimary SurveyAirway (with cervical spine protection)

Patients with airway compromise may need acute airway management to avoid a preventable cause of hypoxia. Always maintain cervical spine immobilization by applying devices as described below in section (d).

(a) Assess airway

- ☐ Stabilize the patient's head by placing a hand on either side of the patient's head prior to communicating with them to protect the C-spine
- ☐ Talk to the patient to establish patency, evaluate for voice change and stridor
- ☐ Perform a general inspection looking for pooling of secretions, cyanosis, facial injuries or expanding haematomas
- ☐ Is the patient conscious or unconscious?
- ☐ Consider use of a naso or oropharyngeal airway during bag-valve mask ventilations (BVM)
- ☐ Rapid Sequence intubation if needed for airway stabilization or protection *i.e.*, for Glasgow Coma Scale (GCS) of 9 or less
- ☐ Consider surgical airway if difficulty intubating in patients unable to maintain their own airway.

(b) Improve airway

Most common form of airway obstruction is a prolapsed tongue, thus manoeuvres below may help to clear the airway:

- Head Tilt/Chin Lift (*Only use this method once C-spine injury has been excluded*)

Place one of your hands on the patient's forehead and apply gentle, firm, backward pressure using the palm of your hand. Place the fingers of the other hand under the bony part of the chin. Lift the chin forward and support the jaw, helping to tilt the head back (**Figure 1**). This manoeuvre will lift the patient's tongue away from the back of the throat and provide an adequate airway. If the head tilt / chin lift is not possible, or is contraindicated (possible cervical spine injury), then the jaw thrust manoeuvre can be performed.

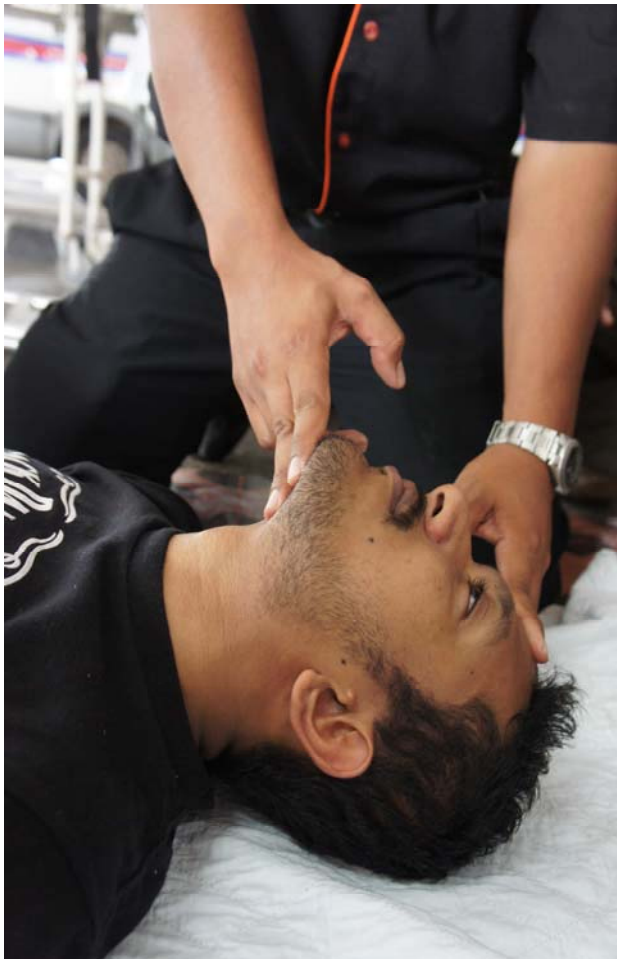

Figure 1: The head tilt/chin lift manoeuvre

- Jaw thrust

Grasp angles of the patient's lower jaw and lift with both hands, one on each side (**Figure 2**). This will displace the mandible forward and prevent the tongue obstructing

the hypopharynx. Care must be taken to prevent extension of the neck whilst performing this manoeuvre.

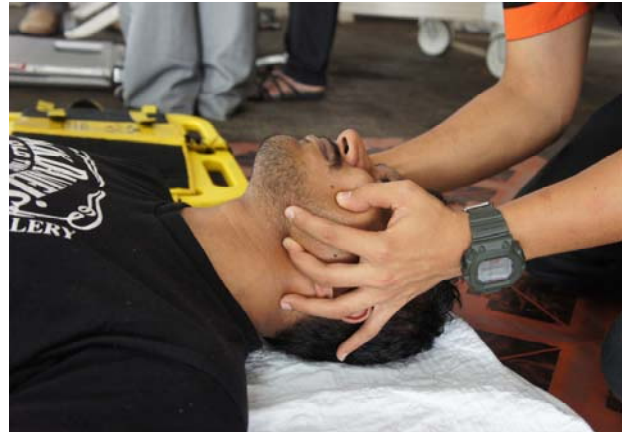

Figure 2: Jaw thrust

(c) Remove foreign bodies

The oral cavity is inspected. Any visible debris is removed manually and secretion is cleared via suction.

(d) Cervical spine immobilization

Devices such as cervical collar and head immobilizer (consisting of head blocks and straps) should be placed on patient prior to patient movement (**Figure 3**). If no collar can be made to fit patient, towel or blanket rolls may be used to support neutral head alignment. The head must be supported at all times prior to exclusion of C-spine injuries, hence prior to use of collar and immobilisers or if they are removed at any point (e.g., when log-rolling to perform a full examination), neutral alignment must be maintained manually with a hand placed on either side of the patient's head. Use rigid spinal boards during patient transfer to prevent unstable fractures causing further neurological deficits.



Figure 3: Cervical collar and head immobilizer in place

Top
Tips

Box 1

Suspect cervical spine injury if**there is:**

- ✓ N – neurological deficit
- ✓ S – spinal tenderness
- ✓ A – altered mental status
- ✓ I – intoxication of drug/alcohol
- ✓ D – distracting injury

Top
Tips

Box 2

Seven life threatening thoracic**conditions:**

- ✓ A – airway obstruction
- ✓ T – tension pneumothorax
- ✓ O – open pneumothorax
- ✓ M – massive haemothorax
- ✓ F – flail chest
- ✓ C – cardiac tamponade
- ✓ H – severe haemorrhage

Breathing

Place your ear near the victim's nose and mouth with your eyes looking towards their chest. Inspect for difficulty in breathing, asymmetrical chest movements, or see-saw appearance. In infants, intercostal recession may be present. Listen for breath sounds (normal, laboured or shallow) or abnormal sounds *i.e.*, complete silence (complete obstruction), cough or wheeze (bronchoconstriction). Feel for breathing, the absence of which may indicate inadequate air moving through the nose or mouth.

The respiratory rate is often the most sensitive indicator of sick patients. Monitor the respiratory rate (normally between 12 to 25) by calculating the breaths per minute (BPM) rate by counting the chest movements 15 seconds, then multiplying by four. Treat hypoventilation and identify seven life threatening thoracic conditions (see **Box 2**).

Give the patient high flow oxygen 15L via a non-breathable mask, even in patients with COPD. In acute situations, hypoxia will kill more quickly than hypercarbia. Once stabilized and the patient shows signs of CO₂ retention, then oxygen levels can be tailored to the individual.

Oxygen treatment can be monitored by blood gas measurements or non-invasively by pulse oximetry. Blood gas analysis provides accurate information on the pH, PaO₂, and PaCO₂. Oximetry provides continuous monitoring of the state of oxygenation.

Circulation

The aim of cardiovascular management is to ensure adequate circulation of blood volume by controlling haemorrhage and replacing lost fluid. Pallor, tachycardia, hypotension, cold, clammy peripheries and a decreased level of consciousness are signs of decreased perfusion. The capillary refill time and pulse rate can be assessed in any setting and is useful in gauging patient's overall perfusion. Any external bleeding should be controlled by applying direct pressure - not tourniquets. Occult blood loss may be from the chest, abdomen, pelvis or from the long bones.

Intravenous access (two large bore lines) should be immediately established followed by fluid resuscitation. Bloods should be sent for cross match. Bladder catheterisation (provided there are no signs of urethral damage) should also be performed to assess urine output.

Continuous bedside monitoring including cardiac monitoring and blood pressure measurements are essential to gauge patient response to ongoing treatment.

The ATLS classification of haemorrhagic shock is illustrated in **Appendix 1**².

Disability (Neurological Evaluation)

A quick assessment of the patient's neurological status can be done using the AVPU scale shown in **Table 1** below:

Component	Description
A - Alert	a fully awake patient
V - Voice	patient responds when verbally addressed
P - Pain	patient responds to painful stimuli
U - Unresponsive	patient does not give any eye, voice or motor response to voice or painful stimuli.

Table 1: AVPU scale

A gross motor/sensory examination is performed to determine if the cranial nerve system is intact. This is not a full neurologic examination. For example, the patient is asked to wiggle his toes to assess motor response to a verbal command. A full neurologic exam is done later in the secondary survey.

Pupils are assessed for size, symmetry and reactivity.

Uncal herniation will present as a "blown pupil." A dilated pupil is seen due to unopposed sympathetic activity.

A more objective way of recording a patient's state of consciousness is by using the GCS (**Table 2**). The best possible score is 15 and the worst score is 3.

Eye Opening Response	Verbal Response	Motor Response
4 - spontaneous	5 – oriented	6 - obeys command
3 - to verbal command	4 – confused	5 - localizes to pain
2 –to pain	3 –inappropriate	4 - withdraws from pain
1 - none	2 –incomprehensible speech	3 - Abnormal (spastic) flexion, decorticate posture
	1 - none	2 - Extensor (rigid) response, decerebrate posture
		1 - none

Table 2: GCS scale

Exposure and Environmental control

Patient should be completely undressed to provide adequate exposure. At the same time, warm blankets should be used to prevent hypothermia.

Finally, log roll the patient using spinal immobilization technique to palpate the spine for step-offs or tenderness (**Figure 4**). To perform the "log roll", at least 5 people are required - three are to manoeuvre the body, one to position the head and lastly one to examine. Steps on performing the log roll are as follow²:

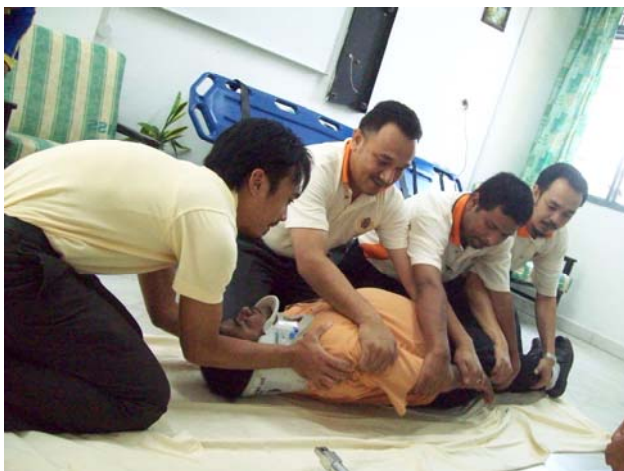

Figure 4: The log roll

- ❑ Apply and maintain cervical stabilization. Assess distal

function in all extremities

- ❑ Apply a cervical collar
- ❑ Rescuers at an appropriate level to the patient *i.e.*, if the patient is on the floor, then three people should kneel on one side of the patient and place hands on the far side of the patient. One person should be at the head and this person should communicate clearly with the rest of the team when to roll the patient.
- ❑ On command, rescuers roll the patient toward themselves, quickly examine the back, slide the backboard under the patient and roll the patient on to the board
- ❑ Position the patient in the middle of the board
- ❑ Secure the upper torso first
- ❑ Secure the chest, pelvis and upper legs
- ❑ Begin to secure the patient's head by using a commercial immobilization device or rolled towels
- ❑ Place tape across the patient's forehead
- ❑ Check all straps and readjust as needed. Reassess distal function in all extremities.

Primary survey adjuncts

Below are investigations that can be done during the primary survey:

- ❑ Standard Trauma X-rays: lateral cervical, AP chest and pelvis
- ❑ Focused Assessment Sonography in Trauma (FAST)
The four views include sub-xiphoid cardiac, spleno-renal, hepato-renal and bladder views. Any free fluid detected during the FAST exam may represent peritoneal penetration

- ❑ Basic laboratory tests should be ordered simultaneously
- ❑ Further x-rays are best grouped and ordered after the secondary survey.

Secondary Survey

Once the primary survey is completed, head to toe evaluation of a trauma patient begins which includes a complete history, full physical examination and reassessment of all vital signs. Each region of the body is fully examined and additional X-rays as indicated by clinical suspicion are obtained.

Top
Tips

Box 3

The hidden eight injuries

include:

- ✓ P – pulmonary contusion
- ✓ A – aortic disruption
- ✓ T – tracheobronchiole disruption
- ✓ M – myocardial contusion
- ✓ E – esophageal disruption
- ✓ T – traumatic diaphragmatic hernia
- ✓ S – spontaneous haemothorax
- ✓ H – haemothorax

If at any time during the secondary survey the patient deteriorates, another primary survey is carried out as a potential life threat may be present.

Summary of approach to the trauma patient as practised at the Emergency Department, Sultan Abdul Halim Hospital, Sungai Petani, Kedah, Malaysia is illustrated in **Appendix 2**.

B. Management of pelvic fractures

The pelvis comprises of two innominate bones and the sacrum. Trauma to the pelvis results in fractures, which may be stable or unstable in nature. The former is common especially amongst the elderly after a simple fall. Unstable fractures, however results from significant kinetic forces such as a fall from height or a motor vehicle accident which often include an increased risk of associated injuries, morbidity and mortality.

Details of treatment strategies are illustrated in the algorithm³ below (**Figure 5**).

Pre-hospital management of patients including appropriate immobilization, airway protection and initial circulatory support with expedient transport is vital.

Case Study

A 24-year-old gentleman was brought to the Red Zone at the Emergency Department after a motor vehicle accident. Upon arrival, his GCS was 15 however he was clinically pale. His BP was 70/40mmHg and pulse was 125/min. On examination, there was scrotal haematoma with bruising over the suprapubic region.

- ❑ What sort of injury should be suspected?
- ❑ What are the initial investigations to be performed?
- ❑ How should this patient be managed?

Top
Tip

Box 4

Pelvic ring disruption may shear blood vessels such as the pelvic venous plexus or internal iliac arterial system leading to severe haemorrhage *i.e.*, up to 2-3L of blood loss which may be hidden

Upon arrival at ED, pelvic stabilization to help tamponade bleeding in patients with pelvic fractures who are haemodynamically unstable is crucial. Initial treatments include using a pneumatic anti-shock garment (PASG), wrapping a sheet around the pelvis or placing a pelvic binder⁴. A chest radiograph and a FAST should be done promptly to exclude other sources of haemorrhage. If the patient continues to be unstable, arterial angiography and embolization should be considered.

If possible, pelvic fractures should be classified according to the Tile and Young and Burgess Systems. These classifications describe fractures based on integrity of the posterior sacroiliac complex (Tile) or based on mechanism of injury (Young).

If the pelvic fracture type is unstable (Tile B or C; Young and Burgess APC II, APC III, LC II, LC III, VS), the patient will require operative fixation and can be treated with more definitive stabilization, such as an external fixator or a pelvic C-clamp.

The principles of pelvic fracture fixation⁵ are:

- ❑ With complete instability of the posterior ring (*i.e.*, the posterior SI ligaments are disrupted), anterior fixation alone is inadequate

- ❑ With complete instability of the posterior ring and vertical instability, any posterior fixation should be supplemented with some form of anterior stabilization.
- ❑ With partial instability of the pelvic ring (*i.e.*, the posterior SI ligaments are intact), anterior fixation alone is adequate and full weight-bearing may be permitted.

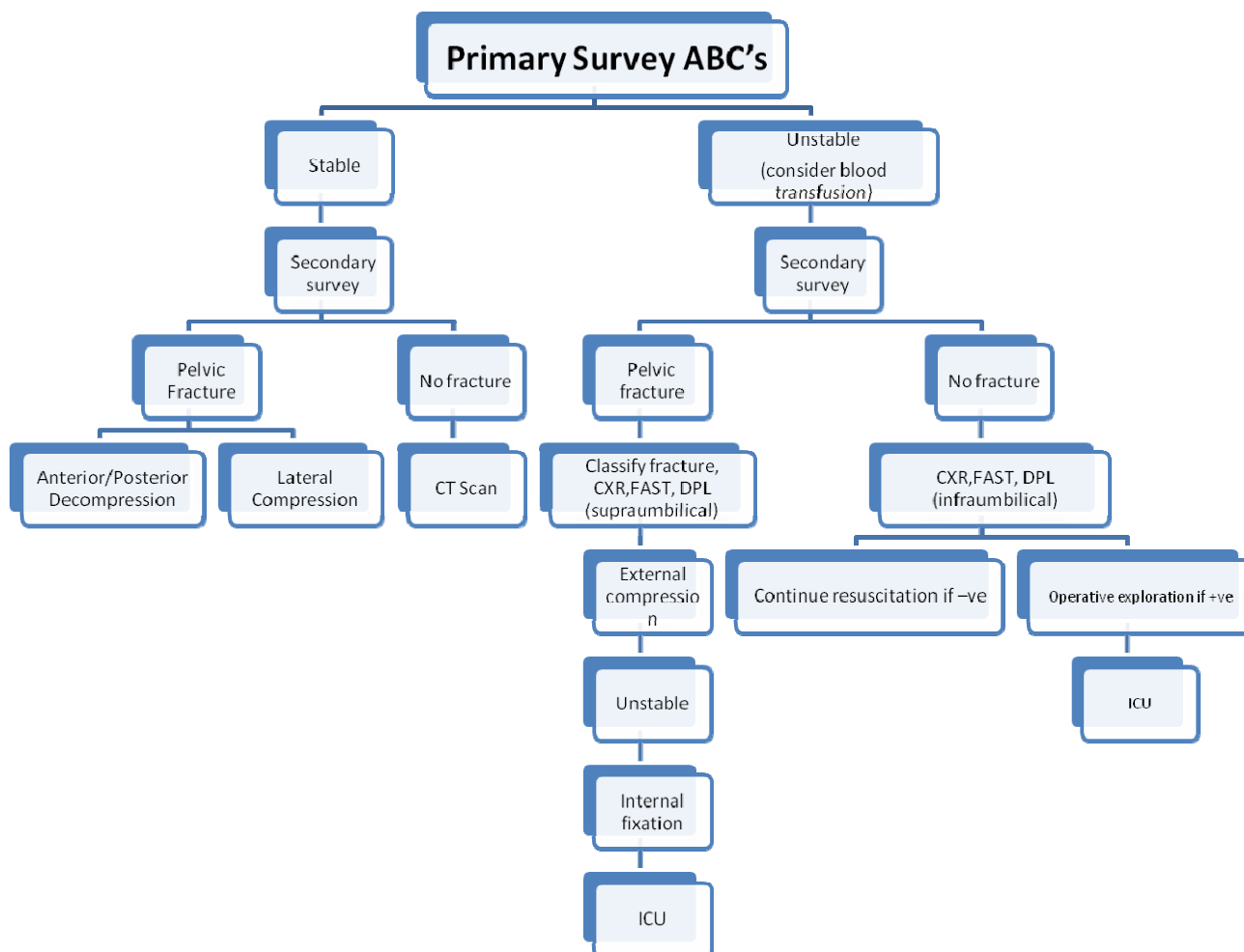


Figure 5: Pelvic fracture management algorithm

C. Management of Acute Abdominal Trauma

Case Study

A 33-year-old lady was brought in by ambulance and was attended promptly by the surgical resident on call. This patient was knocked down by a motorcycle from behind while walking along the roadside. Her vital signs were stable and her GCS was full. Upon examination, there was bruising over the upper abdomen and along her left flank. Also noted, blood stained urine in the catheter bag.

- ❑ What sort of injury should be suspected?
- ❑ What are the initial investigations to be performed?
- ❑ How should this patient be managed?

Abdominal trauma can be broadly divided into penetrating *i.e.*, stab wounds, gunshot wounds or blunt injuries *i.e.*, motor vehicle accidents, falls, assaults and occupational accidents. From an anatomical perspective, abdominal trauma can be categorized into intra-peritoneal, retro-peritoneal and pelvic injuries.

Signs and symptoms include abdominal pain, tenderness, rigidity, distension, haematoma and diminished or absent bowel sounds. Early indications of abdominal trauma include nausea, vomiting, and fever. Haematuria is another salient sign. Seatbelt injuries if significant enough to cause external bruising may have related internal injuries which will also need to be excluded.

Investigations may include ultrasonography, computed tomography, exploratory laparotomy and peritoneal lavage. Treatment may be conservative but if the patient is unstable, he or she will require surgery.

Top
Tip

Box 5

Look for Cullen's sign of periumbilical bruising or Grey-Turner's sign of flank bruising, both associated with retroperitoneal haemorrhage

Hepatic injuries

CT is the recommended diagnostic modality for evaluation of hepatic trauma.

A. Penetrating trauma

- ❑ Initial haemostasis
Rapid mobilization of the injured lobe is done by bimanual compression and perihepatic packing
- ❑ Definitive haemostasis
Deeper wounds are usually managed by hepatotomy and with selective ligation of bleeding vessels
- ❑ Damage control
Perihepatic packing with ICU admission and resuscitation followed by return to the operating room in 24-48 hours

B. Blunt trauma

- ❑ Haemodynamically unstable
Require operative exploration and control of haemorrhage
- ❑ Haemodynamically stable
Patient is treated conservatively whereby ongoing assessment is done to monitor blood loss

Splenic Injuries

A. Penetrating trauma

- ❑ Penetrating splenic injuries are diagnosed at laparotomy. Initial haemostasis is possible through manual compression. Bleeding from small capsular lacerations can be controlled with direct pressure or topical haemostatic agents. In stable patients, splenorrhaphy can be employed⁶. Devitalized tissue should be debrided.

B. Blunt trauma

- ❑ CT remains the diagnostic modality of choice in diagnosing blunt splenic injuries. In stable patients,

close observation with continuous monitoring of vital signs and bed rest is indicated. However, if patient becomes unstable, splenectomy is performed.

Bowel injuries

CT abdomen is the investigation of choice in evaluating abdominal trauma.

A. Small bowel

- ❑ Given its large volume and anatomy, the small bowel is prone to penetrating and blunt trauma (**Figure 6**). Besides imaging, diagnosis can also be made during laparotomy. Treatment consists of primary repair or segmental resection with anastomosis⁷. Mesenteric defects should be closed.

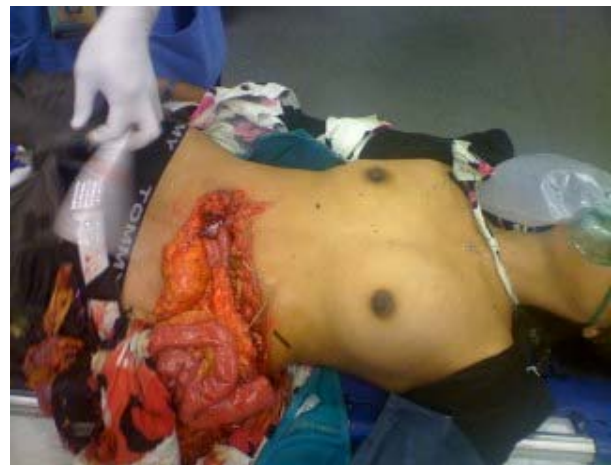

Figure 6: Penetrating bowel injury post motor vehicle accident

B. Large bowel

- ❑ Colonic injuries typically occur secondary to penetrating trauma and are diagnosed at laparotomy. Single agent prophylactic antibiotics are indicated during surgery due to risk of faecal contamination. Primary repair should be considered in all colonic injuries *i.e.*, end to end anastomosis with diverting colostomy.

Kidney injuries

Ultrasound and intravenous pyelogram (IVP) have commonly been used in the past in investigating kidney injuries. Currently, the gold standard in diagnosing kidney injuries is with CT urography.

If the patient is stable and injury to other organ systems has been ruled out, non-surgical treatment is opted. The patient will need bed rest and continuous monitoring to ensure haematuria resolves.

For clinically unstable patients, surgical exploration and kidney repair is indicated. Evidence of kidney dysfunction should prompt arteriography of renal artery. If the injury is discovered within six hours, revascularization is performed. Nephrectomy is indicated if laparotomy is performed for associated injuries⁸.

There are also other less invasive techniques to treat kidney injuries such as angiographic embolization.

D. Management of limb threatening injuries

Case Study

A 45-year-old construction worker had a fall from a 10-foot height platform. Fortunately he landed on a sand pit however he hit his right leg on an edge of a metal frame. Subsequently, he was unable to ambulate and his right calf was grossly swollen. Patient claims there was no head trauma and he remained conscious throughout the event. On further examination, there was a ragged wound noted over the medial aspect of his right calf measuring 5x2 cm as well as a bony protrusion seen at the proximal tibia with minimal blood oozing from the wound.

- ❑ What type of fracture has this patient sustained?
- ❑ How should this patient be managed?
- ❑ What is the best method of fixation for this injury?

Vascular injury

Penetrating wound and blunt force trauma such as fractures and dislocations may cause arterial and other vascular injuries. This may lead to significant haemorrhage through the open wound and soft tissue.

Assessment

Injured extremities should be assessed for external bleeding, loss of previously palpable pulses and change in pulse quality. A cold, pale and pulseless extremity indicates an interruption of the arterial supply. A rapidly expanding hematoma also suggests a significant vascular injury. Doppler Ultrasound is a useful tool to check for pulses.

Management

Before surgery, the application of tourniquet is lifesaving. It is not advisable to apply vascular clamps in bleeding open wounds unless a superficial vessel is clearly identified. During surgery, arterial repair and sometimes arteriography is done⁹.

Crush Injury

Crush injury of the limbs can lead to crush syndrome or traumatic rhabdomyolysis (**Figure 7**). A combination of muscle ischaemia and cell death releases myoglobin which can cause acute renal failure. As a result, elevated creatine kinase levels in these patients may precipitate disseminated intravascular coagulation (DIC)¹⁰.

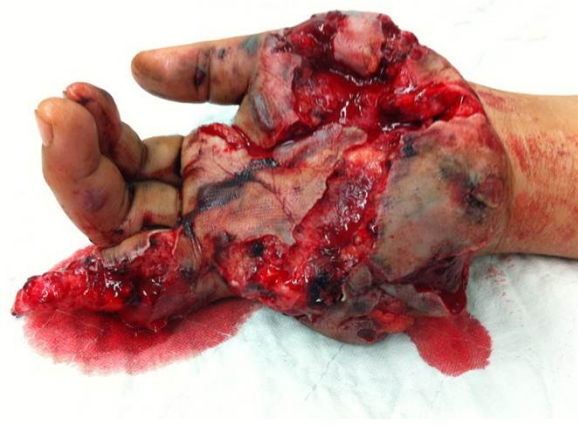

Figure 7: Crush injury caused by sugarcane grinder machine

Assessment

Dark amber urine that may test positive for haemoglobin is a useful indicator for rhabdomyolysis in this clinical scenario. Rhabdomyolysis can lead to hypovolemia, metabolic acidosis, hyperkalemia, hypocalcemia, renal failure and disseminated intravascular coagulopathy.

Management

Fluid resuscitation along with administration of sodium bicarbonate and electrolytes is done to prevent renal failure. Myoglobin induced renal failure can be prevented by intravascular fluid expansion and osmotic diuresis to maintain high tubular volume and urine flow. It is recommended to maintain urinary output at 100ml/hour until the myoglobinuria is cleared. If the limb cannot be salvaged and/or the patient is developing sepsis or severe systemic effects from the trauma, then amputation of the affected limb can be considered.

Compound/open fractures of the lower limb

Open fractures represent a communication between the external environment and the bone. This break in barrier makes fracture sites prone to infection thus subsequently affects healing and may cause loss of function.

The classification of open fracture as described by Gustillo-Anderson is illustrated in **Appendix 3**.

Assessment

Look at size of the wound, extent of soft tissue injury or any signs of neurovascular compromise.

Management

Wound irrigation is done with Normal Saline whereby amount of saline needed depends on severity of the fracture *i.e.*, wounds measuring > 10cm requires at least 9 litres of normal saline irrigation. Additionally, broad

spectrum IV antibiotics should be started.

Wound debridement is compulsory if contamination is noted to be severe. Definitive fixation of the bone is ideally done within 24 hours.

The best method of fixation in open fractures is external fixation or Ilizarov¹¹.

Figures 8-11 illustrate the preoperative and postoperative sequence of management of an open tibia/fibula fracture.

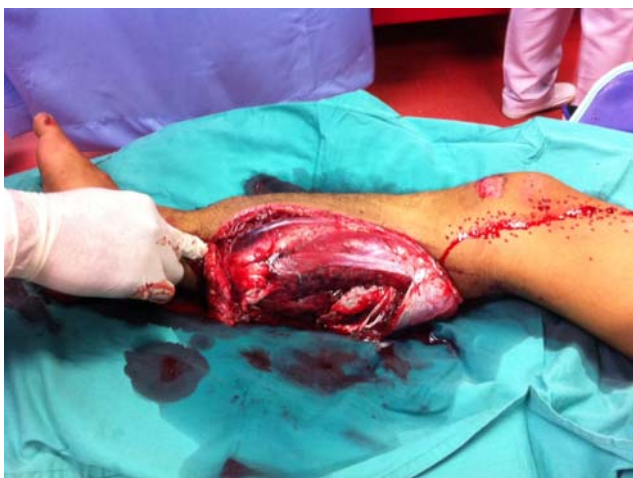

Figure 8: Grade IIIB open distal tibia/fibula fracture. The wound size measures > 10cm and soft tissue is severely damaged. However, there is no vascular involvement

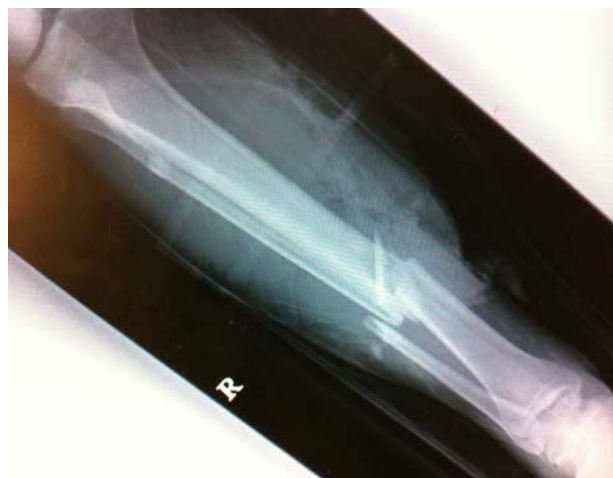

Figure 9: An AP view of a distal comminuted tibia/fibula fracture with butterfly fragment

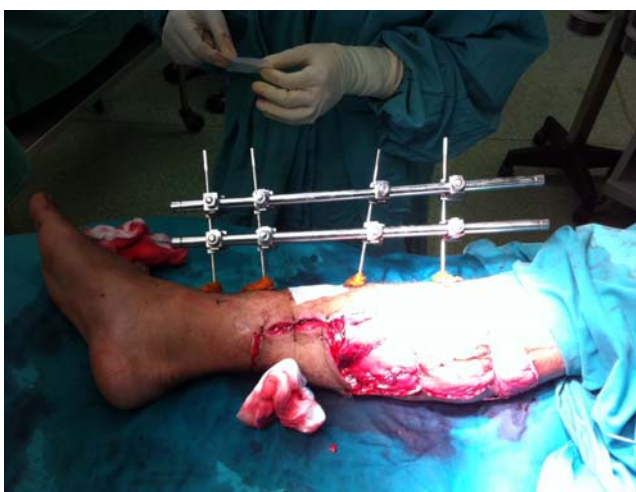

Figure 10: Post-operative application of biplanar external fixation at the fracture site

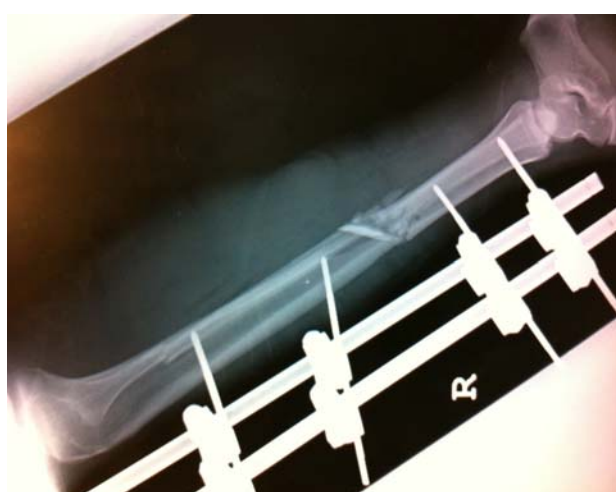

Figure 11: Lateral view of biplanar external fixation under radiological imaging

Top
Tips

Box 6

Acute compartment syndrome usually develops after a severe injury and the clinical manifestations can be described as the 6Ps:

- ✓ Pain
- ✓ Pressure
- ✓ Paraesthesia
- ✓ Paralysis
- ✓ Pallor
- ✓ Pulselessness

E. Management of amputation to limbs or digits

Case Study

A 5-year-old boy was injured after a firecracker he lit went off unexpectedly. He was rushed to the nearest hospital as his left hand was blown apart. At the Emergency Department, his father managed to bring in the detached part (left hand) in a plastic bag filled with ice within 1 hour post trauma.

- ☐ Is the detached left hand salvageable?
- ☐ What are the contraindications for replantation in amputated limbs?
- ☐ How should this patient be managed?

An amputation is a surgical or traumatic separation of a particular body part from its origin (**Figure 8**).

Amputations involving the upper limb or children are usually prioritized when selecting candidates for replantation. Clean cut injuries with minimal contamination are associated with higher rates of successful replantation.

Contraindications for replantation of amputated limbs include coexisting serious injuries or disease that preclude a prolonged operative time, multiple levels of amputation, severely crush or degloving injury, dirty mangled wound, prolonged ischaemia time and mentally unstable patients or self-inflicted wound⁶.

Handling of amputated limb part

The goal is to preserve the limb for reattachment. Therefore, delays in transportation should be avoided. The amputated part should be covered with saline moistened gauze and sealed in a clear plastic bag on a

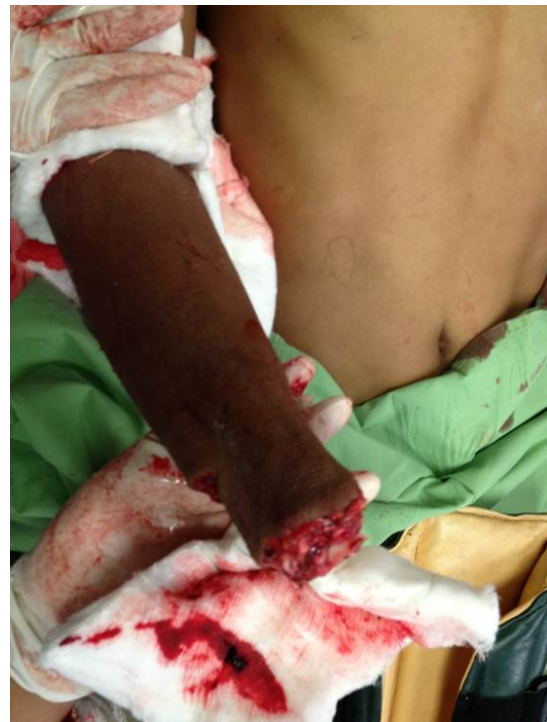

Figure 12: Amputated right hand after a 'parang' assault

mixture of ice and water. The part should never be placed directly on ice or immersed in saline¹².

Amputation repair techniques

The aim is to preserve residual limb length balanced with soft tissue as well as reconstruction to ensure good healing, non-tender and functioning residual limb. The proximal stump is cleaned and a compressive dressing is applied. Tourniquets are not used. The sequence of repair involves identification of affected structures, debriding edges for reattachment, stabilizing bone by using plates, screws or external fixation. The amputated bony edges must be well smoothed. After providing bone stability, the arteries are repaired, followed by repair of the tendon and then veins and nerves. As for the skin, a tension free flap may be attempted or alternatively, a skin graft can be done.

Top
Tip

Box 7

The acceptable window period for replantation (ischaemia time) is 6 hours for proximal limb amputations and 12 hours for fingers.⁶

Rehabilitation

Limb amputation should not be viewed as a failure but as a way of enabling the patient to function at a higher level. The importance of approaching amputation with a positive, constructive frame of mind cannot be overemphasized. On-going, long term rehabilitation aids patients particularly those facing difficulties with prosthetic fitting, the residual limb, performing specific activities and psychosocial adjustment.

Conclusion

Pre-hospital treatment along with prior preparation of the resuscitation room is the key to successful trauma management. Establishment of a trauma team whereby

there is efficient coordination between emergency room physicians and trauma surgeons is vital to ensure a satisfactory final outcome. The advanced trauma life support algorithm provides a good basis in identifying life threatening conditions rapidly as well as stabilizing patients to buy time for definitive assessment. Assessment of the trauma patient must involve a full assessment of the actual and potential injuries with the appreciation that resuscitation is often on-going and the patient's condition can change dramatically at any point of time. Prompt recognition and identification of patients requiring immediate surgery is often life-saving and provides a chance for patients to make a better recovery.

Appendices

Appendix 1: ATLS classification of haemorrhagic shock

	Heart Rate	Blood Pressure	CNS status	Urine output	Blood Loss	Treatment
Class I	<100	Normal	Slightly anxious	>30ml/hr	<15%	Normal Saline
Class II	>100	Normal	Mildly anxious	20-30	15 - 30%	Normal Saline
Class III	>120	Decreased	Confused	5-15	30 - 40%	NS + Blood
Class IV	>140	Decreased	Lethargic	nil	>40%	NS + Blood

Appendix 2: Approach to the Trauma Patient practised at Sultan Abdul Halim Hospital, Sungai Petani, Kedah, Malaysia

PRIMARY SURVEY

		Assess and Identify	Immediate Management
A	AIRWAY + Cervical Immobilization	A Airway obstruction	Blood/secretion <input type="checkbox"/> suction/remove debris Floppy tongue <input type="checkbox"/> oropharyngeal airway Maxillo-facial injury <input type="checkbox"/> attempt reduction, intubation, cricothyrotomy Mechanical blockade <input type="checkbox"/> finger sweep and removal of foreign object Partially obstructed airway <input type="checkbox"/> jaw thrust/chin lift
B	BREATHING	T Tension pneumothorax Clinical diagnosis, not radiological <input type="checkbox"/> Tracheal deviation <input type="checkbox"/> Respiratory distress <input type="checkbox"/> Absence of breath sounds – unilateral <input type="checkbox"/> Distended neck vein Cyanosis – late sign	Needle thoracocentesis Chest tube insertion
		O Open pneumothorax "Open sucking chest wound"	*Do not remove object * Cover defect with 'sterile occlusive dressing' Chest tube insertion Definitive surgical closure
C	CIRCULATION	M Massive haemothorax 1500mls immediately evacuated or 200mls/hour for 3 hours or 300mls/hour for 2 hours Paediatric – 30mls/kg/hour	Rapid volume restoration Chest tube for chest compression Thoracotomy
		F Flail chest When three or more adjacent ribs are fractured at two points	Adequate ventilation and oxygen Volume restoration Analgesia Chest tube if required
		C Cardiac tamponade Beck's triad <input type="checkbox"/> Muffled heart sounds <input type="checkbox"/> Distended neck veins <input type="checkbox"/> Elevated JVP Narrowed pulse pressure Kussmaul's sign FAST – pericardial effusion	Pericardiocentesis Open thoracotomy
		H Severe Haemorrhage Eg: Total amputation	Control bleeding Fluid replacement Blood transfusion Intraosseouscannulation
D	DISABILITY	Assess conscious level (AVPU), GCS and pupil size	For definitive airway if GCS<8

*Survey Adjuncts: Xrays - lateral cervical, chest and pelvic as well as FAST

SECONDARY SURVEY

Assess	Identify	Management
Further History + examination	Identify "hidden eight injuries" PATMET + SH	
AMPLE history Head to Toe Examination A – Allergy M – Medication P – Past medical illness L – Last meal E – Event	P – pulmonary contusion A – aortic disruption T – tracheobronchiole disruption M – myocardial contusion E – esophageal disruption T – traumatic diaphragmatic hernia S – spontaneous haemothorax H – haemothorax	Advanced intervention Adjuncts and tests

Appendix 3: Gustillo-Anderson classification of open fractures

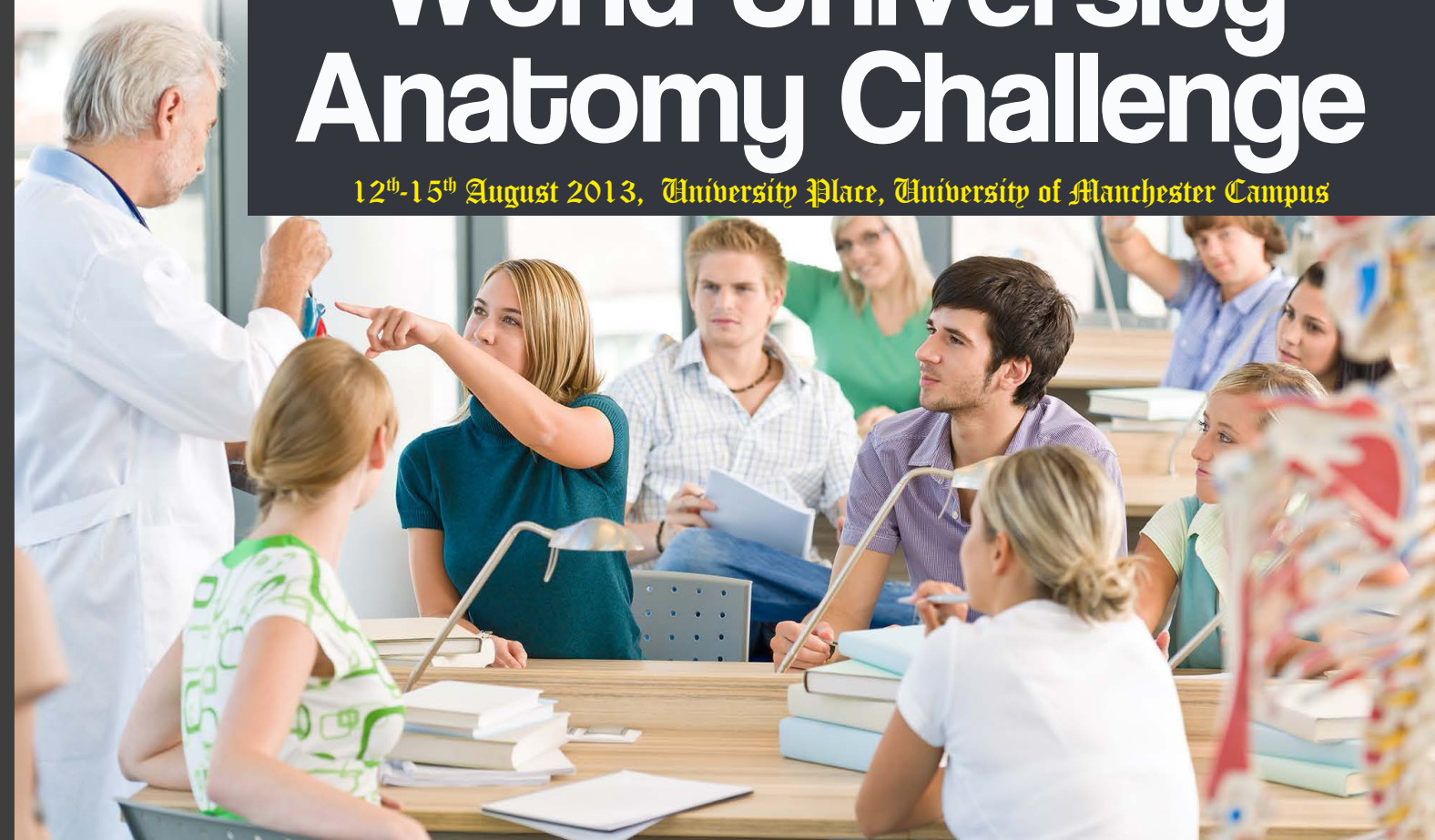
Grade 1	<input type="checkbox"/> Wound < 1 cm <input type="checkbox"/> clean <input type="checkbox"/> simple bone fracture with minimal comminution
Grade 2	<input type="checkbox"/> Wound > 1 cm <input type="checkbox"/> no extensive soft tissue damage <input type="checkbox"/> minimal crushing <input type="checkbox"/> moderate comminution and contamination
Grade 3	<input type="checkbox"/> Extensive skin damage with muscle and neurovascular involvement <input type="checkbox"/> High-speed crush injury <input type="checkbox"/> Segmental or highly comminuted fracture <input type="checkbox"/> Segmental diaphyseal loss <input type="checkbox"/> Wound from high velocity weapon <input type="checkbox"/> Extensive contamination of the wound bed <input type="checkbox"/> Any size open injury with farm contamination
3A	<input type="checkbox"/> Extensive laceration of soft tissues with bone fragments covered <input type="checkbox"/> usually high-speed traumas with severe comminution or segmental fractures
3B	<input type="checkbox"/> Extensive lesion of soft tissues with periosteal stripping and contamination <input type="checkbox"/> severe comminution due to high-speed traumas <input type="checkbox"/> usually requires replacement of exposed bone with a local or free flap as a cover
3C	<input type="checkbox"/> Exposed fracture with arterial damage that requires repair

References:

1. Wrathall, G. The Management of Major Trauma. Updates in Anaesthesia.1996; Issue 6, p. 1-9.
2. American College of Surgeons. Advanced Trauma Life Support for Doctors, ATLS: Student Course Manual. American College of Surgeons, Eighth edition.2008; p.49-55.
3. Durkin A, Sagi H, Durham R, *et al.* Contemporary management of pelvic fractures. The American Journal of Surgery.2006;192, p.211–223.
4. McCormackR, Strauss E, AlwattarB, *et al.* Diagnosis and Management of Pelvic Fractures. Bulletin of the NYU Hospital for Joint Diseases. 2010;68(4), p.281-291.
5. Mohanty K, Musso D, Powell JN, *et al.* Emergent management of pelvic ring injuries: an update. Can J Surg. 2005;48(1), p.49-56.
6. Klingensmith ME, Chen LE, Glasgow SC, Goers PA, Melby SJ. The Washington Manual of Surgery. Lippincott Williams & Wilkins, 5th edition. 2008; p. 381-385.
7. Abenamar M, Najarian S, Michael P, Valenziano M, Carl P. Practice Management Guidelines for the Evaluation of Blunt Abdominal Trauma. The EAST Practice Management Guidelines; 2001.
8. Moore EE, Dunn EL, Moore JB, Thompson JS. Penetrating abdominal trauma index.The Journal of Trauma. 1981;21(6), p.439-445.
9. Haemodynamic monitoring in shock and implications for management. International Consensus Conference, Paris, France, 27-28 April 2006.
10. Smith J, Greaves I.Crush Injury and Crush Syndrome. A Review
11. Journal of Trauma-Injury Infection & Critical Care. May, 2003; Volume 54, Issue 5, p.226-230.
12. Davis G, Fortune C, Bone J. Compound fractures. Joint Surg Am. Jan, 1943;25(1) p.97-120.
13. Helfet D, Howey T, Sanders R, Johansen K. Limb Salvage Versus Amputation: Preliminary Results of the Mangled Extremity Severity Score. July, 1990; Volume 256.
14. National Trauma Database January 2009 to December 2009, Fourth Report. National Trauma Database And Clinical Research centre, Ministry of Health Malaysia. July, 2011; p. 23-47.

World University Anatomy Challenge

12th-15th August 2013, University Place, University of Manchester Campus





The World Journal of Medical Education & Research (WJMER) is the online publication of the Doctors Academy Group of Educational Establishments. It aims to promote academia and research amongst all members of the multi-disciplinary healthcare team including doctors, dentists, scientists, and students of these specialties from all parts of the world. The journal intends to encourage the healthy transfer of knowledge, opinions and expertise between those who have the benefit of cutting-edge technology and those who need to innovate within their resource constraints. It is our hope that this interaction will help develop medical knowledge & enhance the possibility of providing optimal clinical care in different settings all over the world.



WJMER
World Journal of Medical Education and Research
An Official Publication of the Education and Research Division of Doctors Academy