

# **The landmark technique remains a safe alternative to ultrasound guidance for performing a fascia iliacus block: A cadaveric study**

**GHE Robertson; SN Rupasinghe; AB Scrimshire; JS Dunn**

**February 2014**

**Volume 5**

**Issue 1**

**Doctors Academy Publications**

Regional anaesthesia and nerve blocks are a vital part of modern anaesthesia. They can be used on their own, as part of a general anaesthetic or post-operatively as an adjunct to standard analgesia.

A commonly used nerve block is the fascia iliacus block.<sup>3</sup> This can be used in the emergency department as an effective form of pain relief for femoral fractures.



**DOCTORS**  
**ACADEMY**  
Disseminating Medical Knowledge and Skills Globally



# WJMER

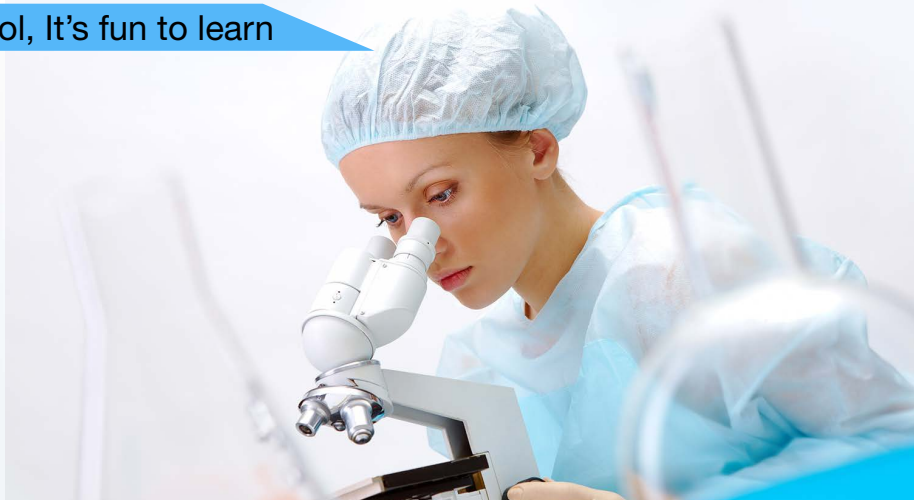World Journal of Medical Education and Research

*An Official Publication of the Education and Research Division of Doctors Academy*

5<sup>th</sup> International Medical Summer School, It's fun to learn



A career in Military Medicine



An Introduction to Emergency Medicine

Anatomy of Trauma, Emergency Medicine and Operative Procedures



Using a microfluidic device to investigate the role of the furry (FRY) gene in Dictyostelium discoideum.

The landmark technique remains a safe alternative to ultrasound guidance for performing a Fascia iliaca block: A cadaveric study

How does addiction occur?

The diagnostic work-up of stable chest pain at a large university teaching hospital

Interview with Professor Laurence Kirmayer, Director of Cultural Psychiatry

### Introduction

The World Journal of Medical Education and Research (WJMER) (ISSN 2052-1715) is an online publication of the Doctors Academy Group of Educational Establishments. Published on a quarterly basis, the aim of the journal is to promote academia and research amongst members of the multi-disciplinary healthcare team including doctors, dentists, scientists, and students of these specialties from around the world. The principal objective of this journal is to encourage the aforementioned, from developing countries in particular, to publish their work. The journal intends to promote the healthy transfer of knowledge, opinions and expertise between those who have the benefit of cutting edge technology and those who need to innovate within their resource constraints. It is our hope that this will help to develop medical knowledge and to provide optimal clinical care in different settings. We envisage an incessant stream of information flowing along the channels that WJMER will create and that a surfeit of ideas will be gleaned from this process. We look forward to sharing these experiences with our readers in our editions. We are honoured to welcome you to WJMER.

### Editorial Board

#### Executive Committee

##### Editor-in-Chief

Professor Stuart Enoch, PhD, MBBS, MRCSEd, PGCert (Med Sci), MRCS (Eng)

##### Editor

Ms. Karen Au -Yeung, BSc, MBCh (Hons), MRCS

#### Associate Editors

Dr. Ahmed Hankir, MBChB

Ms. Laura Derbyshire, MBChB, MRCS

#### Advisory Board

Dr. Mohammed Hankir, BSc, MSc, PhD

Mr. Rajive Jose, MBBS, MS (Gen Surg), MCh (Plast Surg), DNB (Gen Surg), FRCSEd, Dip Hand Surgery (BSSH), FRCS (Plast Surg)

Dr. Suzanne Kumar, MBCh (Hons), MRCP

Mr. Sri Thrumurthy, MBChB (Hons), MRCS

Dr. Jamil David, BDS, MSc, PhD

Dr. Bina Raju, BDS, MSc, PhD

Mr. Vaikunthan Rajaratnam, MBBS (Mal), AM (Mal), FRCS (Ed), FRCS (Glasg), FICS (USA), MBA, Dip Hand Surgery (Eur), PG Cert MedEd (Dundee), FHEA(UK)

Dr. Charlotte Li, MSc, MB ChB

Dr. Leslie Cheng, MSc, MB ChB

Dr. Mayura Damanhuri, MBChB (Hons)

#### ALL RIGHTS RESERVED

Volume 5, Issue 1, 2014, World Journal of Medical Education and Research (WJMER). An Official Publication of the Education and Research Division of Doctors Academy Group of Educational Establishments.

Electronic version

published at

Print version printed

and published at

ISBN

Designing and Setting

Cover page design and graphics

Type Setting

Contact

Doctors Academy, PO Box 4283,

: Cardiff, CF14 8GN, United Kingdom

: Abbey Bookbinding and Print Co.,

: Unit 3, Gabalfa Workshops, Clos

Menter, Cardiff CF14 3AY

: 978-93-80573-33-5

: Doctors Academy, DA House, Judges Paradise, Kaimanam,

Trivandrum, 695018, Kerala, India

: Sreekanth S.S

: Lakshmi Sreekanth

: wjmer@doctorsacademy.org.uk

Copyright: This journal is copyrighted to the Doctors Academy Group of Educational Establishments. Users are not allowed to modify, edit or amend the contents of this journal. No part of this journal should be copied or reproduced, electronically or in hard version, or be used for electronic presentation or publication without prior explicit written permission of the editorial and executive board of WJMER. You may contact us at: wjmer@doctorsacademy.org.uk

## The landmark technique remains a safe alternative to ultrasound guidance for performing a fascia iliacus block: A cadaveric study

**Dr Gillian Hilda Elizabeth Robertson, BSc MBChB**

Foundation Doctor  
Stockport NHS Foundation Trust

**Mr Sukitha Namal Rupasinghe, MBChB MRCS**

Hepatobiliary Research Fellow and Honorary Registrar  
Central Manchester and Manchester Children's  
University Hospitals NHS Foundation Trust

*Address for Correspondence:*

Mr. S.N. Rupasinghe: [namalr@gmail.com](mailto:namalr@gmail.com)

**Dr Ashley Brian Scrimshire, MBChB**

Core Surgical Trainee (Orthopaedics)  
North West Deanery

**Dr John Shaw-Dunn, BSc MBChB PhD FRCS AIAS**

Senior Lecturer in Anatomy  
University of Glasgow

### Keywords:

*Regional block, Anaesthesia, Fascia iliacus, nerve block, Cadaveric study, Landmark technique*

### Introduction

Regional anaesthesia and nerve blocks are a vital part of modern anaesthesia. They can be used on their own, as part of a general anaesthetic or post-operatively as an adjunct to standard analgesia.

A commonly used nerve block is the fascia iliacus block.<sup>3</sup> This can be used in the emergency department as an effective form of pain relief for femoral fractures.

Classically the landmark technique was used, this involves infiltration of local anaesthetic in relation to fixed bony landmarks. However, with the advent of affordable portable ultrasound machines, ultrasound (USS) guided techniques have become more commonplace. This allows for more accurate placement of the block using a reduced volume of local anaesthetic.<sup>1,2</sup>

Usage of USS for regional blocks has been found to be safe and effective. USS guided regional blockade is provided almost solely by anaesthetists and anaesthetic trainees. Blocks performed by non-anaesthetic trainees (for example emergency medicine trainees in accident and emergency departments or orthopaedic trainees) are generally done using the landmark technique.<sup>6,7</sup> This technique can be used effectively by doctors who do not possess the necessary ultrasound skills.<sup>7</sup>

We used a cadaveric model to assess the safety and potential efficacy of the landmark technique for fascia iliacus nerve blocks.

### Method

A single ninety year cadaver donated to the Laboratory of human anatomy of the University of Glasgow was used for the study. Local ethical approval was granted.

The cadaver was prepared and pre-dissected as described later. A single right sided fascia iliacus block was administered by an anaesthetist not directly affiliated with the project using the landmark technique. Blue india ink was used instead of an anaesthetic agent.

### Preparation

The cadaver was prepared using standard embalming techniques and then dissected along fascial planes in the following manner.

A superficial skin incision was made on the right limb from the anterior superior iliac spine (ASIS) to the pubic tubercle, along the line of the inguinal ligament. A vertical incision was then made laterally along the line between the anterior and posterior surfaces of the thigh, finishing just above the knee joint. The lower end of the incision was then extended medially, finishing at the

medial border of the thigh. Starting laterally, a large skin flap was dissected and turned medially to hinge on the medial border of the thigh. Subcutaneous fat and fascia lata were then dissected together and turned medially as a second flap. This was then closed and sutured for the experimental part to begin. This was done so there would be minimal disruption of the tissues post infiltration of anaesthetic.

#### *Infiltration*

The block was introduced using the following landmarks. A line was drawn between the ASIS and pubic tubercle. This line was then divided into thirds and a 18 French Gauge spinal needle was introduced at ninety degrees perpendicularly at 2cm below the point at the junction between the lateral third and the medial third.

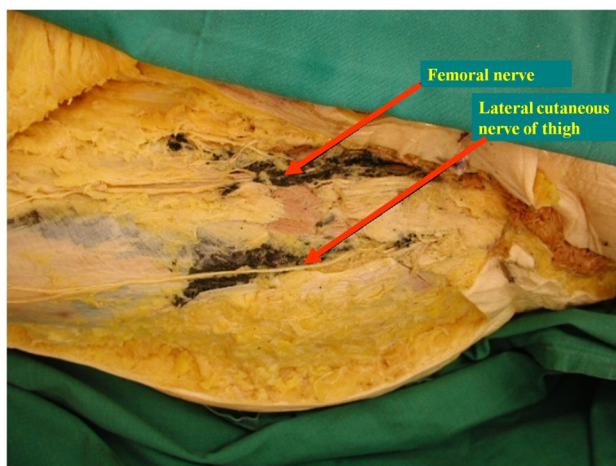
The anaesthetist felt for the first click followed by the loss of resistance as the point for instilling the block. When he was satisfied the tip was in the correct position 20ml of India ink mixed with 10% latex was used and left for 10 days to set.

#### *Inspection*

Subsequently the flap was re-opened to investigate the spread of the India Ink. The abdomen was also opened and carefully inspected for any sign of ink.

Photographs were taken using a Nikon Coolpix 955 digital camera. Images were viewed digitally using Jasc Paintshop Pro (Version 7.04) and stored as .jpeg images.

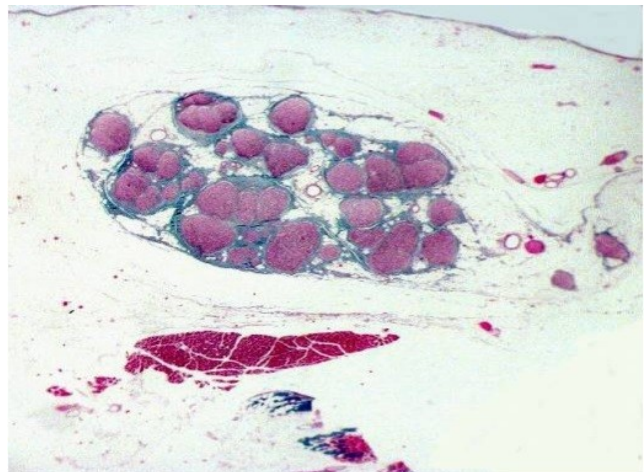
Part of the femoral nerve was excised with a small fragment of muscle en-block from the area where the Femoral nerve was crossing into the right iliac fossa The tissue was then routinely processed for histology.



**Figure 1:** Dissection of thigh. Note the black discoloration in the plane

#### **Results**

Examination of the abdomen did not show any Ink into the abdominal cavity. Dissection of the thigh showed the ink travelling in columns cranially to caudally, covering the femoral and lateral cutaneous nerve of thigh (see figure 1). The ink was contained exclusively in this plane. No sign of vascular or nerve injury was noted at the time of inspection.



**Figure 2:** Histological specimen of thigh dissection. Femoral Nerve centre (pink), covered in ink

Histological examination showed satisfactory covering of the femoral nerve with the india ink as seen in figure 2. The femoral nerve which appears pink was immersed in dark ink at the microscopic level.

#### **Discussion**

There has only been one randomized control trial comparing ultrasound versus the landmark technique for fascia iliaca blocks<sup>4</sup> (non-cadaveric). This study found that there was increased sensory loss with the use of the ultrasound guided method.

However less technical equipment and ultrasound skill is required to use the landmark technique and can be used in the emergency setting as a preoperative adjunct to pain relief prior to surgery.

Our study shows that the landmark technique can be an effective alternative to using ultrasound guidance where this is not available and in experienced hands. We would advocate that persons performing fascia Iliaca blocks should become competent at using both ultrasound guidance and landmark techniques to use in instances where ultrasound facilities are not readily available.

While studies have used similar methods to ours to describe new methods of fascia iliaca blocks,<sup>5</sup> we have shown in our study is that this classical method is still safe and our method of evaluating the spread of the

block suggests that it is likely to be effective. A study with non-anaesthetic staff involved to perform the infiltration will useful to further validate its use role in the emergency setting.

### Conclusion

While we do not recommend the landmark technique

over the USS technique, we conclude that the landmark technique for performing a fascia iliaca block is safe in experienced hands. However repeating this study with non-anaesthetic staff would be useful to evaluate efficacy when performed by non-anaesthetic personnel.

**Competing Interests:** None declared.

### References:

1. P. Marhofer and W. Harrop-Griffiths. Nerve location in regional anaesthesia: finding what lies beneath the skin. Br. J. Anaesth. (2011) 106 (1): 3-5 doi:10.1093/bja/aeq358
2. P. Marhofer, W. Harrop-Griffiths, H. Willschke, and L. Kirchmair. Editor's Choice: Fifteen years of ultrasound guidance in regional anaesthesia: Part 2—Recent developments in block techniques. Br. J. Anaesth. (2010) 104 (6): 673-683 first published online April 23, 2010 doi:10.1093/bja/aeq086
3. Bernard Dalens, Guy Vanneuville, and Alain Tanguy . Comparison of the Fascia Iliaca Compartment Block with the 3-in-1 Block in Children. Anesth Analg December 1989 69:705-713
4. Dolan J, Williams A, Murney E, Smith M, Kenny GN. Ultrasound guided fascia iliaca block: a comparison with the loss of resistance technique. Reg Anesth Pain Med. 2008 Nov-Dec;33(6):526-31.
5. Hebbard P, Ivanusic J, Sha S. Ultrasound-guided supra-inguinal fascia iliaca block: a cadaveric evaluation of a novel approach. Anaesthesia. 2011 Apr;66(4):300-5. doi: 10.1111/j.1365-2044.2011.06628.x. Epub 2011 Feb 24.
6. Rashid A, Beswick E, Galitzine S, Fitton L. Regional analgesia in the emergency department for hip fractures: survey of current UK practice and its impact on services in a teaching hospital. Emerg Med J. 2013 Jul 22. doi: 10.1136/emered-2013-202794.
7. Fujihara Y, Fukunishi S, Nishio S, Miura J, Koyanagi S, Yoshiya S. Fascia iliaca compartment block: its efficacy in pain control for patients with proximal femoral fracture. 1. J Orthop Sci. 2013 Jun 7. [Epub ahead of print]



The World Journal of Medical Education & Research (WJMER) is the online publication of the Doctors Academy Group of Educational Establishments. It aims to promote academia and research amongst all members of the multi-disciplinary healthcare team including doctors, dentists, scientists, and students of these specialties from all parts of the world. The journal intends to encourage the healthy transfer of knowledge, opinions and expertise between those who have the benefit of cutting-edge technology and those who need to innovate within their resource constraints. It is our hope that this interaction will help develop medical knowledge & enhance the possibility of providing optimal clinical care in different settings all over the world.



# WJMER

World Journal of Medical Education and Research  
*An Official Publication of the Education and Research Division of Doctors Academy*