

# Endoscopic Retrieval of Impacted Gallstone in the Rectum

**Alchoikani N; Comez T; Zammit M**

**March 2016**

**Volume 11**

**Issue 1**

**Doctors Academy Publications**

Gallstone ileus is an uncommon cause of a mechanical bowel obstruction (1 -3%)<sup>1</sup>, where a gallstone passes into the small bowel via cholecysto-enteric fistula, and impacts in the terminal ileum. Even more rarely, the stone might pass to large bowel where only few reported cases have diagnosed gallstones in the rectum.



**DOCTORS  
ACADEMY**



**BETTER EDUCATION. BETTER HEALTH.**



# WJMER

**World Journal of Medical Education and Research**

An Official Publication of the Education and Research Division of Doctors Academy

Bridging the Gap Using ENT Emergency Clinics

How We Devised and Implemented Foundation Trainee Led Audit Poster Days -  
an Engaging and Popular Means of Teaching Audit Process

Defining the Role of a Medical Student during a Sub-Internship

Education Curriculum of Circumcising Males to Reduce the Spread of HIV/Aids in a  
Non-circumcising Community: Logical Analysis of the Practice Among the Luo of Kenya

Parent-Child Resilience in Cleft Lip or/and Palate Condition: A Review

Mallet Finger Injuries - A Review Article

Perceptions of the Effectiveness of Mentoring Programme among Medical Students In a  
Private University in Selangor, Malaysia

Endoscopic Retrieval of Impacted Gallstone in the Rectum

**DOCTORS ACADEMY**



BETTER EDUCATION. BETTER HEALTH.

ISSN 2052-1715





## Endoscopic Retrieval of Impacted Gallstone in the Rectum

Alchoikani N; Comez T; Zammit M

### Institution

Basildon and Thurrock  
University Hospitals NHS  
Foundation Trust,  
Nethermayne, Basildon,  
Essex

**WJMER, Vol 11: Issue 1,  
2016**

### Abstract

**Introduction:** Gallstone ileus is an uncommon cause of a mechanical bowel obstruction (1-3%)<sup>1</sup>, where a gallstone passes into the small bowel via cholecysto-enteric fistula, and impacts in the terminal ileum. Even more rarely, the stone might pass to large bowel where only few reported cases have diagnosed gallstones in the rectum.

**Presentation of Case:** In our case, an 83 year old lady, known to have a history of 4cm gallbladder stone, was admitted for management of ileus that was thought to be due to hypokalemia; However, a gallstone in the rectum was missed on the abdominal X-ray. Patient was discharged only to be readmitted few days later with on-going obstructive symptoms and was found to have the gallstone impacted in the rectum on CT colonogram. The stone was successfully retrieved endoscopically.

**Discussion:** Although cases have been reported of spontaneous passage of rectal stones, in this case the large gallstone remained impacted in the rectum and caused mechanical obstruction. A successful catheter-aided extraction of gallstone in rectum under local anaesthesia has previously been reported. In our case, Flexible sigmoidoscopy was used to evacuate 4 cm gallstone successfully.

**Conclusion:** Gallstone ileus is rare but well-documented cause of bowel obstruction, and it is always paramount to look for radiological features of gallstone ileus. Gallstones impacted in the rectum are even more uncommon and can be managed by endoscopic retrieval.

### Key Words

General Surgery; Gallstone; Rectum; Endoscopy; Gallstone Ileus; Flexible Sigmoidoscopy

### Corresponding Author:

Mr Alchoikani N: E-mail: nasibalchoikani@gmail.com

### Introduction:

Gallstone ileus is an uncommon cause of a mechanical bowel obstruction (1-3%)<sup>1</sup>, where a gallstone passes into the small bowel via cholecysto-enteric fistula, and impacts in the terminal ileum. Even more rarely, the stone might pass to large bowel, with only few reported cases of gallstones impacted in the rectum.

### Presentation of Case:

In our case, an 83 year old lady, known to have a history of 4cm gallbladder stone, was admitted to hospital complaining of abdominal pain, nausea and vomiting. She was managed as a suspected paralytic ileus secondary to hypokalemia; However, a gallstone in the rectum was missed on the abdominal X-ray that also showed dilated bowel loops (Figure 1). After correcting the patient's potassium level her symptoms improved and she was discharged back to nursing home. However, a

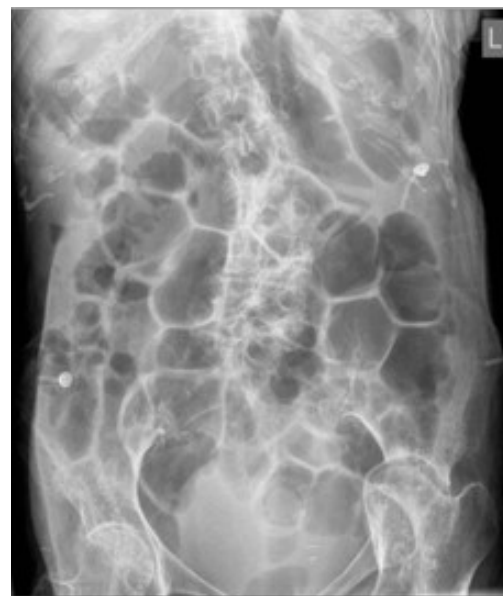
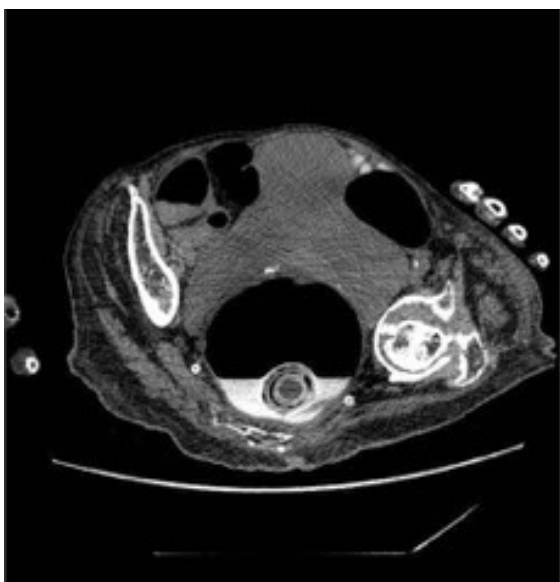
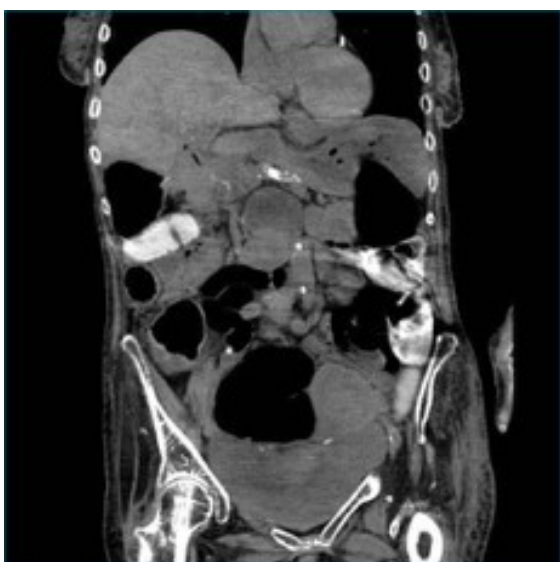Figure 1

few days later, the patient was re-referred by her GP, with the same symptoms. The patient was re-admitted and again found to have severe hypokalemia with dilated bowel on an abdominal x-ray. The plain film on this admission did not show the gallstone in the rectum, as the x-ray missed the pelvis.

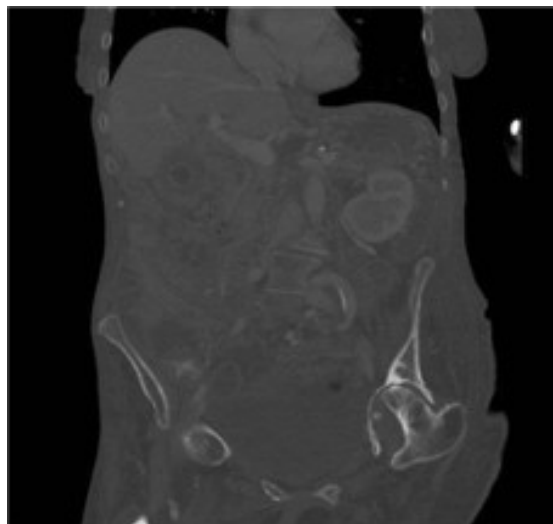
The initial clinical picture was again thought to be in-keeping with paralytic ileus/pseudo-obstruction secondary to hypokalaemia. A CT Colonography was done showing a gallstone present within the rectum (Figure 2), with pneumobilia (Figure 3). This gallstone was previously noted to be within the gallbladder on a CT examination done few months earlier (Figure 4).



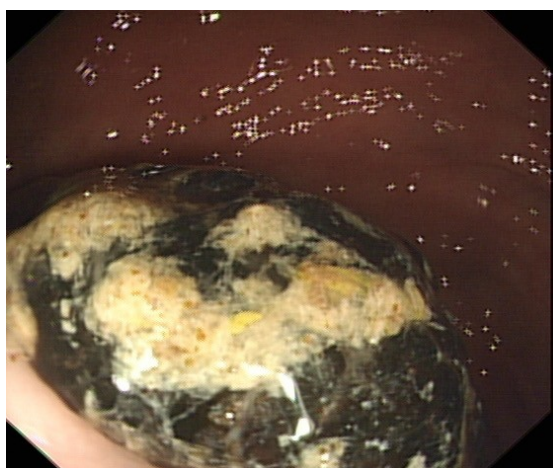
*Figure 2*



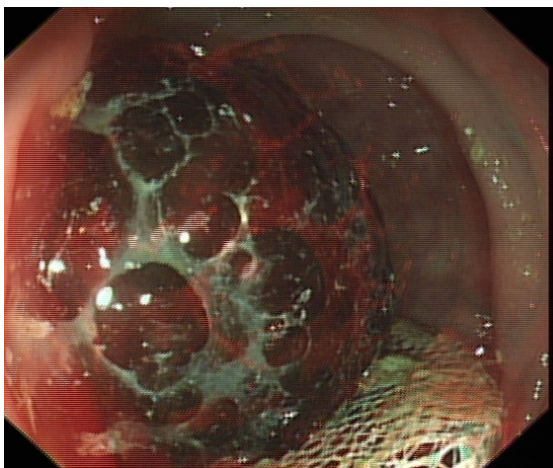
*Figure 3*



*Figure 4*



*Figure 5*



*Figure 6*

The patient had a flexi-sigmoidoscopy with successful retrieval of the gallstone using a large snare. (Figure 5,6). Following this, her symptoms



completely settled down, and she was discharged from hospital.

**Discussion:**

Few rare cases of spontaneous evacuation of gallstone from rectum have been documented, yet such an expectant management could be painful to the patient<sup>2</sup>. A successful catheter-aided extraction of gallstone in rectum under local anaesthesia has been reported<sup>3</sup>. In our case, flexible sigmoidoscopy was used to evacuate the gallstone successfully despite its large size (4 cm).

**Conclusion:**

Gallstone ileus is rare but well-documented cause of bowel obstruction; It is paramount to look for mechanical causes of bowel obstruction. Large, impacted rectal gallstones can be removed endoscopically, avoiding the need for an anaesthetic.

**Highlights:**

- 1- Gallstone ileus is rare but documented cause of bowel obstruction.
- 2- It is always paramount to look for obvious mechanical cause on X-ray.
- 3- Impacted gallstone in the rectum could possibly be an indication for flex-sigmoidoscopy.

**References**

1. Buetow, GW, Crampton, RS. Gallstone ileus. Archives of surgery. 1963. Vol 86, pg 504-11.
2. Gordon, AJ. An unusually large gallstone passed by rectum. The Journal of the American Medical Association. 1924. Vol 83, pg 2015.
3. Skulstad, SM, Olsen, LE, Rukke, O. Intestinal Obstruction by a Large Gallstone in the Rectum: Successful Catheter-aided Extraction. European Journal of Surgery 2000. Vol 166, pg 422-25.



The World Journal of Medical Education & Research (WJMER) is the online publication of the Doctors Academy Group of Educational Establishments. It aims to promote academia and research amongst all members of the multi-disciplinary healthcare team including doctors, dentists, scientists, and students of these specialties from all parts of the world. The journal intends to encourage the healthy transfer of knowledge, opinions and expertise between those who have the benefit of cutting-edge technology and those who need to innovate within their resource constraints. It is our hope that this interaction will help develop medical knowledge & enhance the possibility of providing optimal clinical care in different settings all over the world.



# WJMER

**World Journal of Medical Education and Research**

An Official Publication of the Education and Research Division of Doctors Academy

ISSN 978-93-80573-47-2



9 789380 573472